

# Cecal volvulus: a case report

Madhusudhanan Devanathan, Bharani K RajKumar, Sasivannan Anbarasu, Medhun Kumar

Department of Surgery, Tagore Medical College and Hospital, Chennai, Tamil Nadu, India.  
Correspondence to: Sasivannan Anbarasu, E-mail: dranbu.sasivannan@gmail.com

Received November 7, 2014. Accepted November 17, 2014

## Abstract

Cecal volvulus is an infrequently encountered clinical condition and an uncommon cause of intestinal obstruction. Patients with this condition may present with highly variable clinical presentations ranging from intermittent, self-limiting abdominal pain to acute abdominal pain associated with intestinal strangulation and sepsis. We present here a case of 54-year-old woman presented to our medical department with left hemiparesis and later on developed intestinal obstruction. She went for series of radiological investigations and was diagnosed as cecal volvulus. She underwent right hemicolectomy and ileocolic anastomosis. Her recovery was uneventful. The lack of familiarity with this condition is a factor contributing to delays in diagnostic and treatment. The objective of this review was to promote clinicians' awareness of this disease through patient-case illustration, discussion of disease pathogenesis, clinical features, and management strategies.

**KEY WORDS:** Cecal dilatation, mobile cecum, volvulus

## Introduction

Volvulus describes the condition in which the bowel becomes twisted on its mesenteric axis, a situation that results in partial or complete obstruction of the bowel lumen and a variable degree of impairment of its blood supply.<sup>[1]</sup> Colonic volvulus commonly affects the sigmoid, cecum, and transverse colon in the decreasing order of frequency with cecal volvulus accounting for 1% of causes of large bowel obstruction and 10%–40% cases of colonic volvulus.<sup>[2]</sup> We present the case of a 54-year-old patient who presented with symptoms of intestinal obstruction and had characteristic radiological findings of a cecal volvulus.

## Case Report

A 54-year-old woman presented to Medicine outpatient department with weakness in left upper and lower limbs and constipation. During evaluation of left hemiparesis she progressively developed abdominal distension, vomiting, and constipation. Surgical call over was given and on examination we

found distended abdomen with sluggish bowel sounds and loaded rectum. On further evaluation with X-ray, abdomen supine showed dilated small-bowel loops [Figure 1]. Hence, initially paralytic ileus was suspected. Patient was treated conservatively and was observed for the next 24 h. Patient was found to deteriorate with progressive symptoms and increasing abdominal girth (from 76 to 84 cm). Thus, patient was evaluated with contrast-enhanced computer tomography (CECT) abdomen, which showed grossly dilated cecum with closed-loop obstruction [Figures 2 and 3].

Patient was taken up for emergency laparotomy for acute intestinal bowel obstruction, and we found freely mobile and

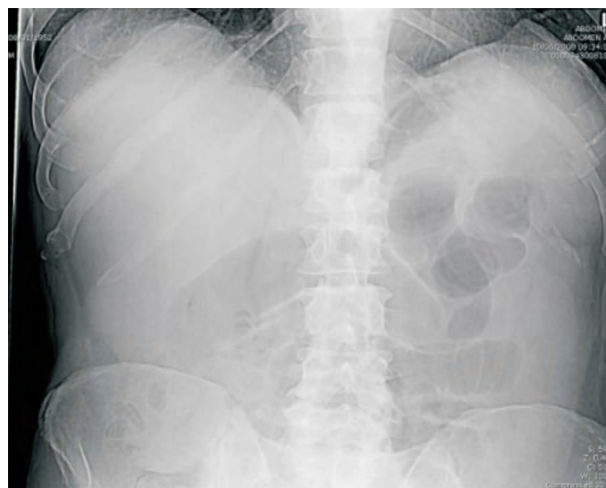


Figure 1: X-ray abdomen supine showed dilated small-bowel loops.

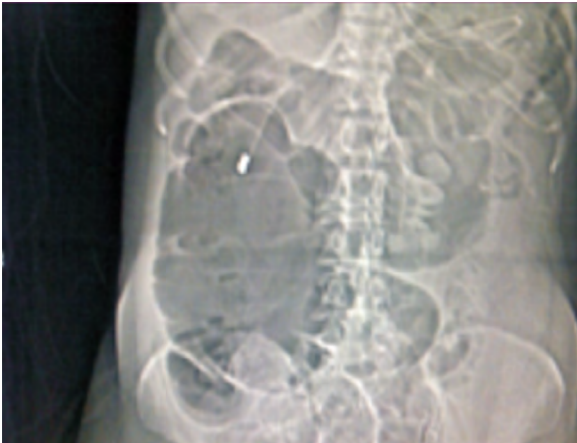
### Access this article online

Website: <http://www.ijmsph.com>

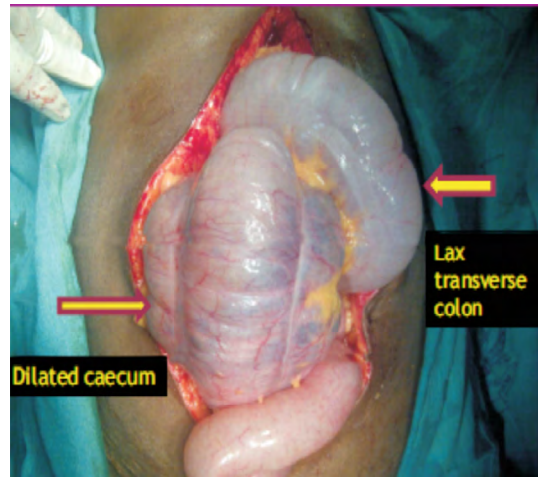
DOI: 10.5455/ijmsph.2015.0711201473

Quick Response Code:

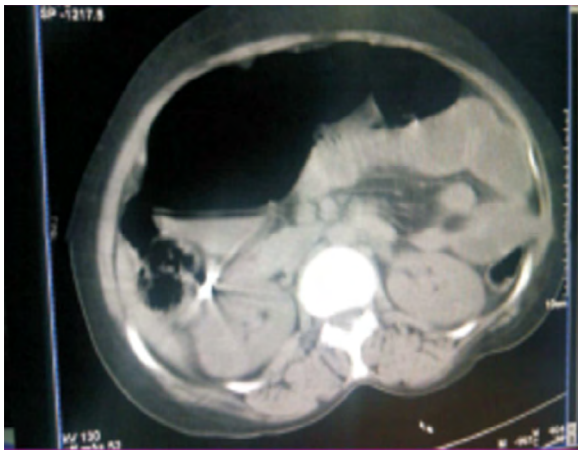



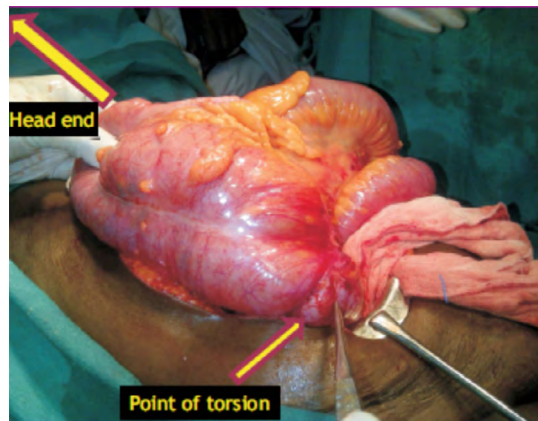
**Figure 2:** CECT showed grossly dilated cecum.



**Figure 4:** Grossly dilated cecum.



**Figure 3:** Grossly dilated cecum with closed-loop obstruction.

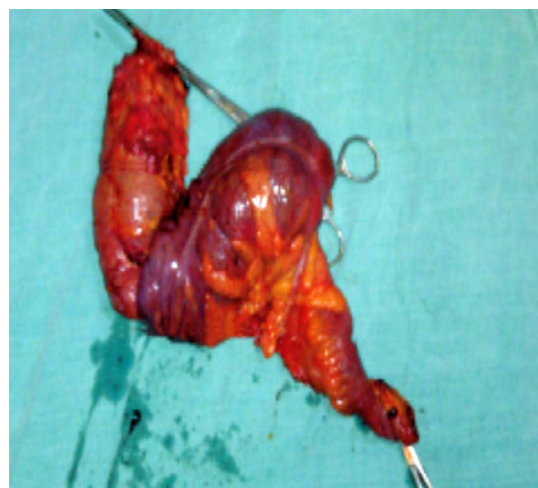

**Figure 5:** Grossly dilated cecum with clockwise axial rotation of ileum, cecum, and ascending colon.

grossly dilated cecum with clockwise axial rotation of ileum, cecum, and ascending colon [Figure 4 and 5]. This was, therefore, removed with right hemicolectomy [Figure 6] and primary ileocolic anastomosis was made. Postoperative period was uneventful. After 1 week, patient was transferred to medical department for the management of left hemiparesis.

## Discussion

Cecal volvulus is relatively a rare condition, accounting for less than 2% of all cases of adult intestinal obstruction.<sup>[1]</sup> The term cecal volvulus is misleading as this process is often not limited to the cecum alone but usually consists of an axial rotation of the terminal ileum, cecum, and ascending colon, with concomitant twisting of the associated mesentery. Cecal volvulus occurs more commonly in females and has been reported in all age groups, with an average age of presentation in the fourth decade.<sup>[3]</sup>



**Figure 6:** Right hemicolectomy specimen.

There are two prerequisites for cecal volvulus to occur, a segment of mobile cecum and ascending colon and a point of fixation about which torsion may occur. The mobility results from either incomplete embryologic rotation of the bowel or improper developmental fusion of the mesentery of the cecum and ascending colon with the posterior parietal peritoneum.<sup>[4]</sup> In addition to the prerequisite of a freely mobile cecum, several additional predisposing factors have been implicated in the genesis of cecal volvulus including previous surgery, pregnancy, malrotation, and obstructing lesions of the left colon.<sup>[1]</sup>

There are two types of cecal volvulus: the axial torsion type and the loop type. In the axial torsion type, as in our present case, the cecum twists in the axial plane, rotating clockwise or counterclockwise around its long axis with the cecum remaining in the right lower quadrant. In the loop type of volvulus, the distended cecum both twists and inverts, moving to occupy the left upper quadrant of the abdomen. Radiological findings may reflect the difference between these types, the dilated cecum was observed in the lower abdomen on CT scans in all cases of the axial torsion type, whereas it was observed in the upper abdomen in all cases of the loop type. There is another variant of cecal volvulus, termed as cecal bascule, which occurs when the cecum folds anteriorly without any torsion.<sup>[5]</sup>

All three types of volvulus result in a closed-loop obstruction at risk of mesenteric ischemia according to Laplace's law. In addition, the axial- and loop-type volvuli have an underlying mesenteric twist that causes vascular strangulation and higher rates of mesenteric ischemia. With all types of cecal volvulus, patients present acutely with nonspecific symptoms of bowel obstruction, including generalized abdominal pain, nausea, vomiting, constipation, and abdominal distension. The acute presentation can be preceded by a recurrent intermittent pattern of symptoms in 50% patients, referred to as the mobile cecum syndrome.<sup>[6]</sup> Physical examination may show asymmetrical distention of the abdomen, with a tympanic mass palpable in the left upper quadrant or mid-abdomen.<sup>[1]</sup>

On plain abdominal radiographs, cecal volvulus is seen as a rounded focal collection of air-distended bowel, with haustral creases, that resembles a "coffee bean" or "comma." Several other findings, such as little or no gas in the distal colon and dilation of small-bowel with air-fluid levels, are known to be useful for the diagnosis of cecal volvulus. However, these findings are not specific and, therefore, may be misinterpreted as small-bowel obstruction, and correct preoperative diagnosis on the basis of plain abdominal radiography findings alone was made in only 17% of cecal volvulus cases. Although barium enema has shown a relatively high diagnostic yield for cecal volvulus, the procedure is somewhat cumbersome and takes a considerable time. Furthermore, the possibility of bowel ischemia or other disease processes outside the bowel wall cannot be evaluated using barium enema.<sup>[6,7]</sup>

In current clinical practice, CECT is used more commonly than barium enema as the diagnostic modality for acute abdomen. The diagnosis of colonic volvulus on CECT is facilitated by following the colon proximally from the rectum. The "bird beak" and "whirl" signs are useful CT findings for identifying the

site of obstruction. The bird beak sign describes the appearance of a bowel loop that progressively tapers and converges at the torsion site. The whirl sign represents swirling strands of soft-tissue attenuation, comprising the twisted loops of bowel and branching mesenteric vessels, against a background of mesenteric fat attenuation, and the whirl sign was observed on CT scans of all patients with colonic volvulus. In another study, the whirl sign was visible in all cases of axial torsion and loop-type cecal volvulus, whereas there was no visible whirl sign in cases of cecal bascule.<sup>[6]</sup>

Options for the management of cecal volvulus include endoscopic decompression, surgical detorsion alone, cecopexy, cecostomy, and right colectomy with primary or delayed anastomosis or proximal stoma—all through open or minimally invasive approaches. Also, like torsion in the sigmoid location, resection is required for those patients with grossly necrotic bowel, yet also must be considered in patients with massive distension involving the very thin-walled cecum. Unlike its left-sided counterpart, endoscopic decompression with cecal volvulus is less successful, with rates ranging from 30% to 50%.<sup>[7]</sup> Thus, when deciding on the appropriate surgical option for cecal volvulus, it is again imperative to weigh the operative morbidity with the risk of recurrence. Simple surgical detorsion alone is plagued by recurrence rates greater than 50%<sup>[8]</sup> as well as not insignificant morbidity and mortality rates of 10%–20%.<sup>[9]</sup> Less extensive procedures such as detorsion with cecopexy have an overall low morbidity of 10%–30%, but still are associated with high recurrence (10%–30%).

With increasing use of minimally invasive techniques, the morbidity associated with cecopexy may decrease, although its effect on long-term recurrence remains to be seen.<sup>[10]</sup> Cecostomy has been associated with even higher complication rates more than 50% in some series and has largely been abandoned.<sup>[9]</sup> More often, surgical resection with primary anastomosis has become the mainstay of therapy, with low morbidity and mortality and recurrence rates <10%. Even in the presence of gangrenous changes, resection of the involved segment with primary anastomosis has shown acceptable results.<sup>[11]</sup> Cecal bascule can be managed with primary resection and anastomosis or cecopexy.<sup>[3]</sup>

## Conclusion

Cecal volvulus is a rare but critical cause of acute abdomen and is associated with a high mortality rate. A high index of suspicion is required for pre-op diagnosis. CECT is considered fundamental in the prompt and accurate diagnosis of cecal volvulus. Conservative management is not recommended because of the high risk of ischemia, and surgical detorsion alone carries a high rate of recurrence (20%–75%).<sup>[12]</sup> Retrospective case series have shown the lowest morbidity and recurrence with surgical cecal resection, as opposed to alternative procedures such as cecopexy and cecostomy.<sup>[13]</sup> Early surgery is the rule. Right hemicolectomy is the treatment of choice.<sup>[1]</sup>

## References

1. Townsend CM. *Sabiston Textbook of Surgery: The Biological Basis of Modern Surgical Practice*, 19th edn., 2012. pp. 1314–6.
2. Jason R, Robert H, Trudy C, Ahmed A-A. Bascule caecal volvulus: a rare cause of intestinal obstruction. *J Surg Case Rep* 2014;4:1-3.
3. Yeo CJ, Matthews JB, McFadden DW, Pemberton JH, Peters JH. *Shackelford's Surgery of the Alimentary Tract*, 7th edn. Saunders: New York, 2012. pp. 1851–5.
4. Mohamed F, Abukhater M, Ahmad B, Mohamed A. Postcesarean section caecal volvulus: case report and literature review. *Intern J Gynaecol Obstet* 2009;14(1). (cited on August 15, 2014) Available from URL: <https://ispub.com/IJGO/14/1/11364>.
5. Matsui Y, Takaoka M, Soda Y, Michisita N, Hayashi J, Yoshida K, et al. A case of caecal volvulus in a cerebral palsy patient: usefulness of multidetector computed tomography for preoperative diagnosis. *Kawasaki Med J* 2012; 38(4):205–9.
6. Farnam J, Wallach M. Caecal volvulus diagnosed on CT in two distinct clinical settings. *R I Med* 2014;97:45–7.
7. Renzulli P, Maurer CA, Netzer P, Buchler MW. Preoperative colonoscopic derotation is beneficial in acute colonic volvulus. *Dig Surg* 2002;19:223–9.
8. Montes H, Wolf J. Cecal volvulus in pregnancy. *Am J Gastroenterol* 1999;94:2554–6.
9. Rabinovici R, Simansky DA, Kaplan O, Mavor E, Manny J. Caecal volvulus. *Dis Colon Rectum* 1990;33:765–9.
10. Tsushimi T, Kurazumi H, Takemoto Y, Oka K, Inokuchi T, Seyama A, et al. Laparoscopic cecopexy for mobile caecal syndrome manifesting as caecal volvulus: report of a case. *Surg Today* 2008;38:359–62.
11. Majeski J. Operative therapy for caecal volvulus combining resection with colopexy. *Am J Surg* 2005;189:211–3.
12. Madiba TE, Thomson SR. The management of cecal volvulus. *Dis Colon Rectum* 2002;45:264–7.
13. Rakinic J. Colonic volvulus. In: *The ASCRS Textbook of Colon and Rectal Surgery*, Beck DE, Roberts PL, Saclaride TJ, et al. (Eds.), 2nd edn. New York: Springer, 2011. pp. 395–406.

**How to cite this article:** Umedani LV. Association of physical activity, nature of job, and exercise with the prevalence of essential hypertension in the Tharparkar desert. *Int J Med Sci Public Health* 2015;4:429-432

**Source of Support:** Nil, **Conflict of Interest:** None declared.